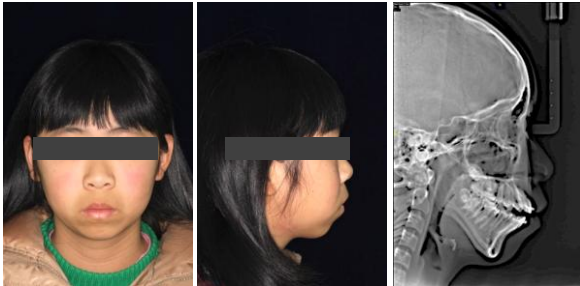


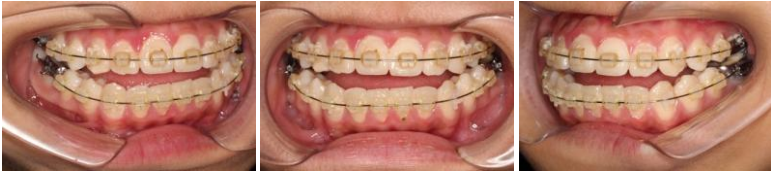# Yang's Combined "TMJ Arthroscopy-Jaw-Occlusion" Treatment

## Preoperative

Facial form

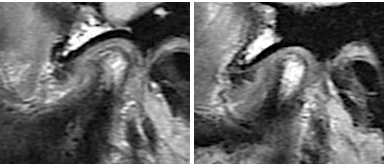


Occlusion — Brackets on the teeth ( another hospital)

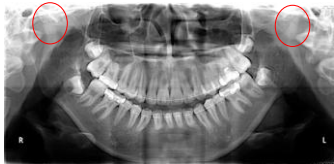

MRI-closed

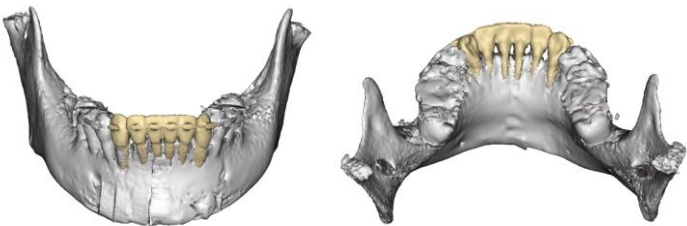
right left



OPG



Alveolar bone defect

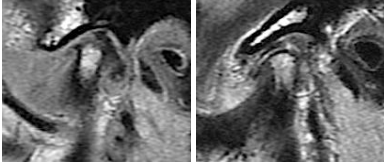


## Postoperative Jaw-Occlusion Treatment

2 days after AS

MRI-closed

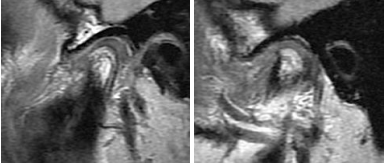
right left



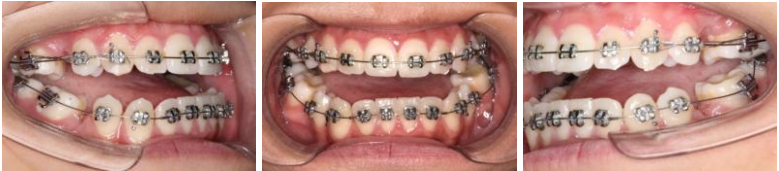6 months after AS

MRI-closed

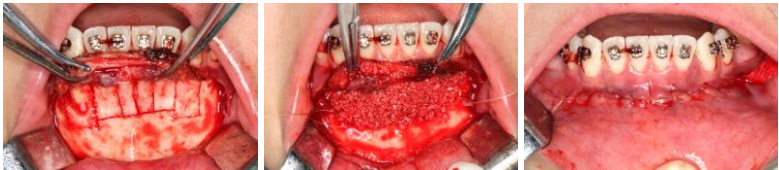right left



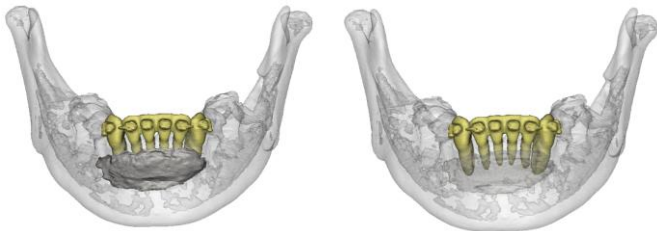Later orthodontic treatment



33 — 43 PAOO

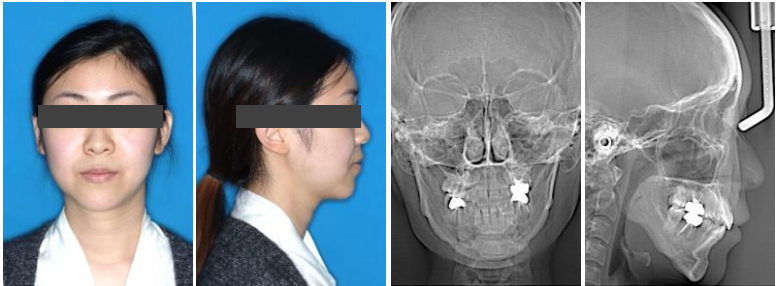


Postoperative 3D reconstruction of PAOO

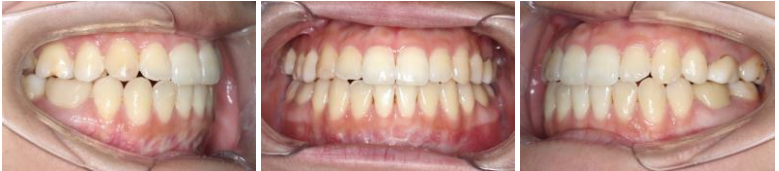

## Postoperative Long-term Follow-Up

10 years after AS (7 years after orthodontics & genioplasty)

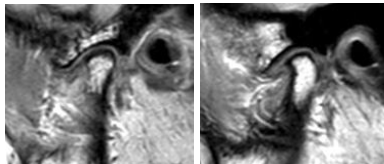


Occlusion

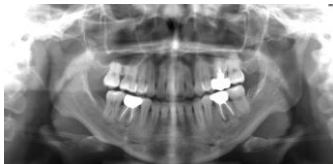

MRI-closed

right left



OPG



Alveolar bone & roots

